

**One Case of a Patient with Umbilical Metastasis of Recurrent
Cancer (Sister Mary Joseph's Nodule, SMJN) Who has Survived for
a Long Time under Immunomodulatory Supplement Therapy**

Tomonori KAWAI

Shinkurashiki icho komon geka

One Case of a Patient with Umbilical Metastasis of Recurrent Cancer (Sister Mary Joseph's Nodule, SMJN) Who has Survived for a Long Time under Immunomodulatory Supplement Therapy

Tomonori KAWAI
Shinkurashiki icho komon geka*

Summary

A 64-year-old female patient with umbilical metastasis of recurrent colorectal cancer (SMJN) was subjected to complementary medicine using the rice bran arabinoxylan derivative¹⁻²⁾, a food component of BRM activity in addition to chemotherapy in order to maintain the QOL and prolong life. Although the umbilical metastasis is tending to grow, the patient is in a good nutritional condition and has survived for more than two years from diagnosis. SMJN is a distant metastasis, and even if it is the first occurrence, radical treatment may not be possible in most cases. This case suggests that the maintenance of the QOL and physiological function may lead to a prolongation of life even in patients with terminal cancer with extremely poor prognosis like this. And this case presents the benefit of supplementary therapy using functional foods.

Key words: colorectal cancer, immunotherapy, rice bran arabinoxylan derivative

Introduction

Umbilical metastasis of malignant tumors in visceral organs is called Sister Mary Joseph's Nodule (SMJN). This is named after Sister Mary Joseph, a nurse working in an operating room, who noticed that gastric-cancer patients with umbilical metastasis had a poor prognosis³⁾. The primary lesion is in the stomach, pancreas, ovary, or large intestine, but the metastasis route is controversial. Our search showed that there are 11 reports on SMJN originated from colorectal cancer (Table 1). We will report the case of a patient with SMJN from the ascending colon who has survived for a long time under chemotherapy and supplement therapy with the immunomodulatory functional food, rice bran arabinoxylan derivative (BioBran).

One Case of a Patient with Umbilical Metastasis of Recurrent Cancer (Sister Mary Joseph's Nodule, SMJN) Who has Survived for a Long Time under Immunomodulatory Supplement Therapy

Tomonori KAWAI (Shinkurashiki icho komon geka) et al.

* 1719, Tamashima, Kurashiki-shi, Okayama 713-8102

Table 1 Cases of umbilical metastasis of colorectal cancer

No.		Age	Sex	Description and size of tumor	Treatment and others	Primary lesion	Complications	Type of cancer cells	Survival
1	Tameaki Matsubara ⁵⁾ 1972	62	Female	2 × 1.5 cm Uneven, elastic hard, reddish brown	New patient	Sigmoid colon	Intestinal obstruction 2 weeks after examination	adenocarcinoma	
2	Shojiro Moriyasu ⁶⁾ 1975	56	Female		New patient	Cecum		cystic papillary adenocarcinoma	
3	Ninako Nakayama ⁷⁾ 1976	58	Female	Soybean sized, red, hard tumor	Numerous metastatic foci in the greater omentum and small intestine Confirmatory operation	Cecum		adenocarcinoma	
4	Keiko Oka ⁸⁾ 1981	58	Male	5 × 4 cm Red and cartilage-hard	New patient 5FU (250 ng/day) and Picibanil (0.1 KE/day) Removal of a tumor on the abdominal wall skin	Ascending colon	Liver metastasis	adenocarcinoma	Died after 11 months
5	Yoshinori Mori ⁹⁾ 1980	45	Female	0.9 × 1.1 cm Milk-white to light yellow Hard, like a plate of a few centimeters around the navel	First patient Krestin (3 g/day)	Ileocecal junction	Liver metastasis, pulmonary edema	adenocarcinoma papillotubulare	Died of hepatic coma pneumonia after 10 months
6	Yuichiro Koizumi ¹⁰⁾ 1985	56	Female	Hemorrhagic umbilical tumor (the size of index finger's nail)	New patient Removal of the primary lesion	Sigmoid colon		adenocarcinoma	
7	Kazuo Sasaki ¹¹⁾ 1987	64	Male	Fingernail sized, elastic hard, hemisphere, red node	New patient Confirmatory operation	Transverse colon		adenocarcinoma (Moderately differentiated)	Died of pneumonia and renal failure after 2 weeks
8	Masashi Kanazawa ¹²⁾ 1992	23	Female	Red/renal-enlarged nodular mass	Old patient 5FU (3500 mg/W) Umbilical resection	Transverse colon	Ovarian and peritoneal metastases	signetring cell + mucinous carcinoma	7 months
9	Yoshifumi Kajimoto ¹³⁾ 1993	67	Female		New patient Tumor removal	Transverse colon	Intestinal obstruction	adenocarcinoma (Moderately differentiated)	3 months
10	Junichi Mizushima et al. ¹⁴⁾ 1995	62	Female	3 × 1.4 cm Bone-like hard, subcutaneous tumor	New patient Tegafur 600 mg/day	Sigmoid colon	Metastatic liver tumor	adenocarcinoma (Moderately differentiated)	2 months
11	Eiji Meguro et al. ¹⁵⁾ 1998	66	Male	3 × 3 cm	New patient Umbilical tumor removal	Sigmoid colon	Peritoneal metastasis Cachexia	adenocarcinoma	20 days
12	Tomonori Kawai This patient	64	Female	3 × 3.7 cm Bone-like hard, reddish-brown tumor	Old patient Immunotherapy, 5FU, Leucovorin, and Topotecin	Ascending colon	Peritoneal metastasis	adenocarcinoma (Well differentiated)	Surviving for 2 years or more, alive

1. Case presentation

- Patient:** Female aged 64
- Main complaint:** Umbilical tumor
- Family history:** (–)
- Medical history:** She was diagnosed as having colorectal cancer in April 2000, and underwent a resection of the ascending colon.
Effusion appeared in January 2001, and an umbilical lump was found.
She received a diagnosis of recurrent cancer, peritoneal dissemination, and umbilical metastasis, and was told that operation was impossible and that her remaining life was several months.
She visited our hospital for immunotherapy on January 29, 2002.
- Present disease:** A 3.0 × 3.9 cm elliptical pink tumor of tooth-like hardness was felt in the navel region, which formed a 7.0 × 5.0 cm unclearly defined mass of the same hardness deep in the abdominal cavity (Figure 1).

Test results at admission

- WBC: 5900/mm³
- RBC: 4,650,000/mm³
- Platelet: 22.7/mm³
- CEA: 6.1 ng/ml
- NK cell activity: 41% (normal 18-40)
- AST/ALT: 17/14
- Abdominal CT (Figure 2)
- Pathological tissue (Figure 3)

The peripheral blood and immunity were normal, but the tumor marker CEA was at a high level of 6.1 ng/ml.

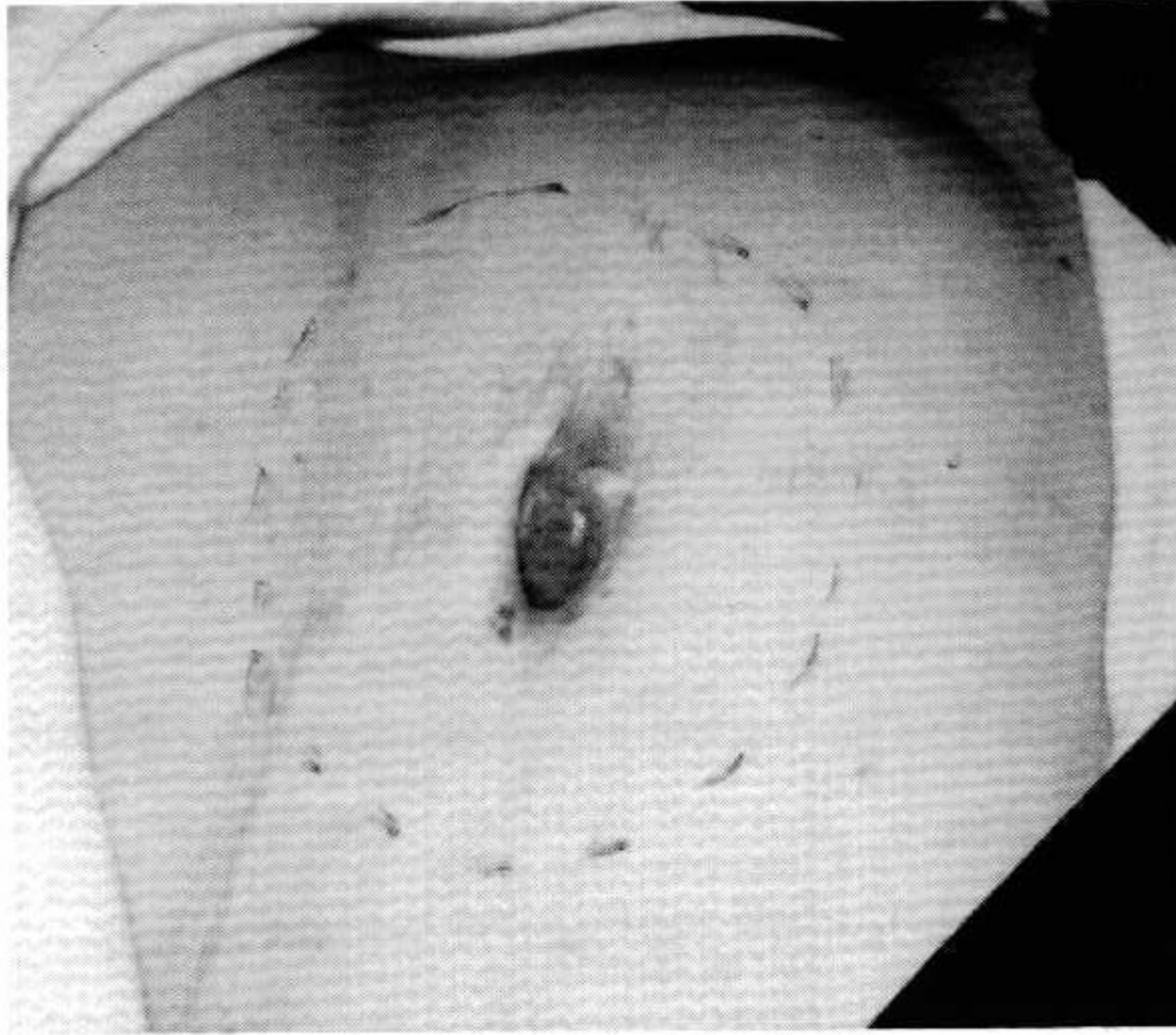

Figure 1

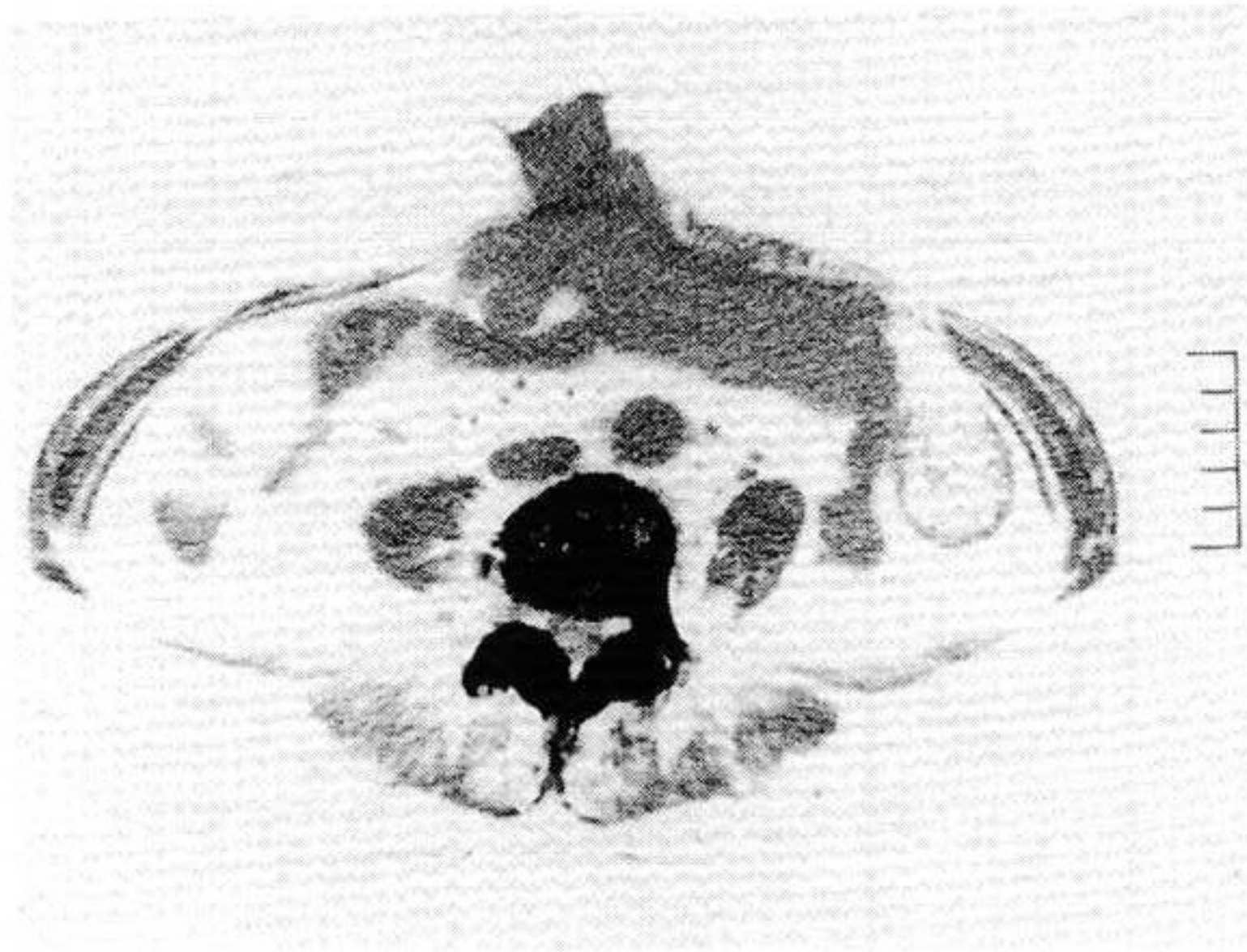


Figure 2

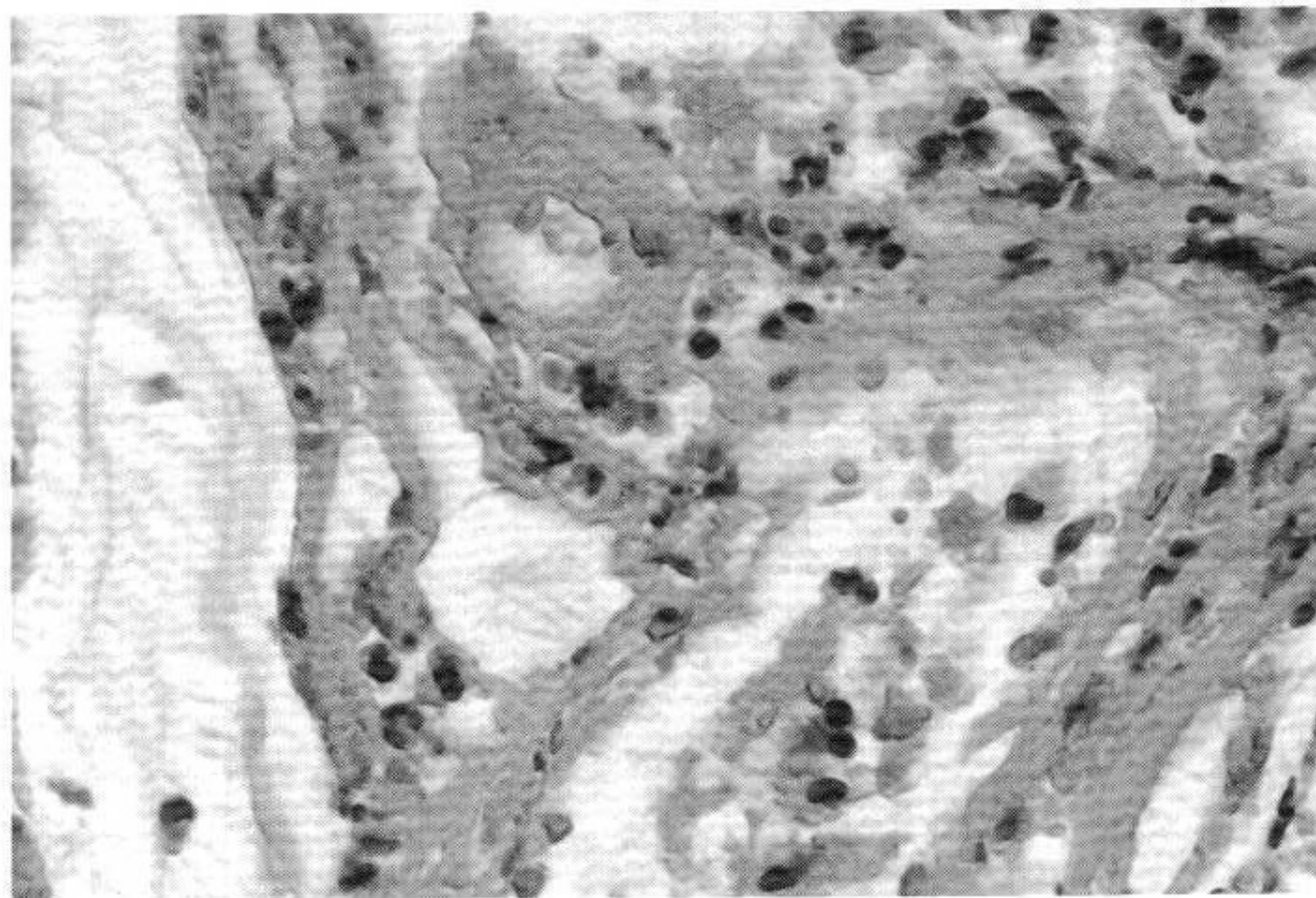


Figure 3

2. Treatment and clinical course

Table 2 shows the content of treatment and clinical course.

The upper section shows changes over time in CEA, WBC count, RBC count, and NK activity. The middle section shows the content of treatment, and the lower indicates the tumor size.

1) January 2002

She rejected administration of anticancer drugs for fear of adverse reactions, and thus immunotherapy only was prescribed. BioBran was taken at 3.0 g/day. The CEA was 6.5 ng/ml and the NK cell activity was 41%. The size of the umbilical tumor was 3.0 × 3.9 cm, and the intraperitoneal mass was 7.0 × 5.0 cm (Figure 2).

She had a good appetite and defecation/flatus once a day, being in good condition. She walked into the consulting room.

2) February 9, 2002

The NK activity increased to 54% at 1 month of BioBran ingestion.

The CEA decreased slightly to 6.1 ng/ml. She said, "The umbilical tumor is unchanged, but the intraperitoneal mass is a little reduced."

3) March 15, 2002

The CEA further decreased to 5.6 ng/ml, and the abdominal tumor was unchanged. BioBran was given for 6 months.

4) July 2002

The NK activity increased to 55%, but the CEA also increased to 12.6 ng/ml.

The umbilical/intraperitoneal mass slightly increased to 5.0 × 6.0/10.0 × 12.0 cm. She had a good appetite and defecation/flatus.

5) December 2002

The umbilical/intraperitoneal mass was 5.0 × 6.0/10.0 × 12.0 cm. The CEA increased to 24 ng/ml. She had a good appetite and defecation/flatus, but said, "My stomach is heavy." Her walking condition was good.

6) April 2003

There was no major change from early 2003, but the CEA gradually increased to 46.8 ng/ml.

A left inguinal lymph node metastasis was noted. A metastasis of 1.2 × 1.2 cm occurred on the left skin and was removed. The umbilical/intraperitoneal tumor increased to 7.0 × 8.0/29.0 × 24.0 cm, and the dose of BioBran was increased to 6 g/day. The umbilical tumor discharged a large volume of effusion and she said, "It is a big problem to keep changing the gauze." However, she traveled sometimes with her daughter.

7) May 2003

The CEA decreased to 38.6 ng/ml. General condition was good. No large change. BioBran was ingested for a total of 1 year and 5 months.

8) July 2003

Since the umbilical/intraperitoneal tumor increased to 9.0 × 11.0/30.0 × 25.0 cm, chemotherapy was performed after obtaining her consent. She said, "It is hard to walk, because my stomach is heavy." The weight of the mass was estimated from the size to be about 3 kg. She had a good appetite and defecation/flatus.

5-Fu 500 mg, Isovorin 250 mg, and 10A + Topotecin 40 mg were administered once a week, but there were no adverse reactions such as nausea, vomiting, diarrhea, and anorexia.

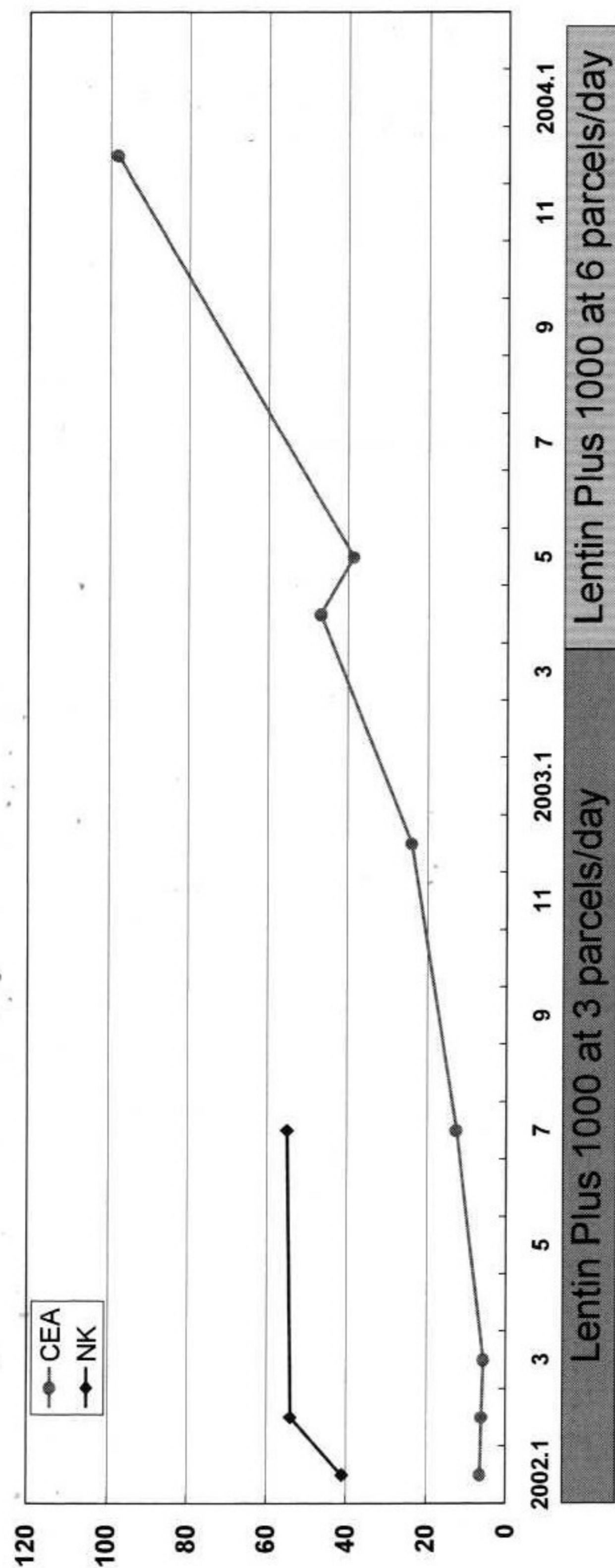
9) October 2003

The tumor partly became necrotic along the blood vessels after the start of chemotherapy, but the necrotic part disappeared and the tumor began to increase again 4 days after the completion of chemotherapy.

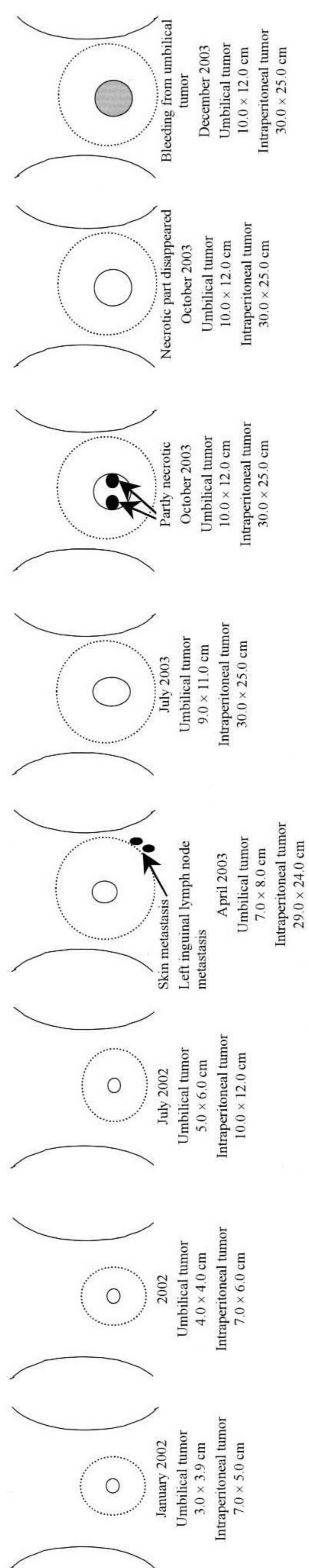
10) December 2003

The CEA increased to 98 ng/ml. She was bleeding from the tumor. In spite of astringent with Oxytzel, Spongel, and Tacho Comb, bleeding recurred. However, anemia was not clear, and the RBC count was 3,000,000/mm³. At her request, the chemotherapy was withdrawn and immunotherapy alone was given. The WBC count increased to 16,900/mm³, which is possibly because of inflammation due to cancer. The chemotherapy caused no myelosuppression. The appetite slightly decreased, but no nausea or vomiting occurred. She weakened and walked with the help of a stick. This was because the enlarged abdomen from the tumor hindered her from walking.

Table 2 Therapy Details and their Progressions



5FU 500 mg/week
 Isovornin 10 A/week
 Topotecin 40 mg/week



11) February 2004

The appetite decreased and she ate only half of a meal. She weakened further and often lay down in bed. She said, "When I walk, I always lean back because of my heavy stomach." She walked along the wall to the lavatory. Malaise was mild. She was still alive on February 17.

Discussion

SMJN originates from primary cancer in the stomach, ovary, pancreas, or other areas, and the mean remaining life is said to be 9.8 months. To the author's knowledge, from 1970 to now, there have been 12 cases of SMJN from colorectal cancer, including this patient (Table 1). Their survival times are from 2 weeks to 11 months, with an average of 4.9 months, which is shorter than those for other SMJN. Our patient has survived for 2 years and 2 months since detection, and there have been no other cases like this. In comparison of survival time and the tumor size at detection, a patient with a tumor of 0.9 cm survived for 10 months (Case 5), and those with a tumor of 3 cm lived for only 2-3 months (Cases 10 and 11). However, a patient with a large tumor of 4 cm survived for 11 months (Case 4).

Although Cases 10 and 11 had the same size tumor (3.0×3.7 cm) and survived for only 2-3 months, our patient has survived for 2 years or more. Based on these, the tumor size is not related to prognosis.

The possible reasons for the long survival in this case are as follows:

- 1) As shown in Table 2, the patient was treated based on immunotherapy, which did not impair the immunity determined as the NK activity.
- 2) Chemotherapy was added, but no myelosuppression occurred.
- 3) BioBran for immunotherapy prevented decreases in physical strength and appetite. The patient also said, "When I take it, I feel better."
- 4) Although the abdominal tumor gradually grew, the intraperitoneal mass was not so large, which prevented organ compression and complications such as intestinal obstruction due to direct invasion of the large and small intestines, and ascites due to peritoneal metastasis. She also had no liver, lung, brain, or bone metastasis, which occurs through hematogenous dissemination.
- 5) BioBran produced no adverse reactions.

These may have protected the patient's QOL and prolonged her life. From now on, she will be followed up using only the immunotherapy.

Bibliography

- 1) Ghoneum, M.: Enhancement of Human Natural Killer Cell Activity by Modified Arabinoxylan from Rice Bran (MGN-3), *INT. IMMUNOTHERAPY XIV* 2: 89-99, 1998
- 2) Jacoby, H., G. Wnorowski, K. Sakata and H. Maeda: The Effect of MGN-3 on Cisplatin and Adriamycin Induced Toxicity in the Rat, *Journal of Nutraceuticals, Functional & Medical Foods In press*, 2000
- 3) Powell, F.C., A.J. Cooper, M.C. Massa, et al.: Sister Mary Joseph's nodule; A clinical and histologic study. *J.Am. Acad. Dermatol.*, 10 : 610-615, 1984
- 4) Hisamoto, K., K. Nishioka, T. Ota, et al.: Cases of Umbilical Metastasis of Pancreatic Carcinoma (Study of Reports on Umbilical Metastasis in Japan for the Past 22 Years), *Clinical Dermatology*, 41: 1097-1102, 1987
- 5) Matsubara, T.: One Case of Umbilical Metastatic Cancer, *The Japanese Journal of Dermatology*, 82: 336, 1972
- 6) Two Cases of Metastatic Cancer, *Nishinippon Journal of Dermatology*, 37: 152, 1975
- 7) Nakayama, N., et al.: Umbilical Metastatic Cancer, 86: 180, 1976
- 8) Oka, K., K. Miyazaki, M. Kouya, et al.: Transepithelial Elimination Found in a Case of Skin Cancer Metastatic, *The Japanese Journal of Dermatology*, 91: 1-6, 1981
- 9) Mori, Y.: One Case of Umbilical Metastatic Cancer, *Rinsho Derma (Tokyo)*, 22: 1141-1146, 1980
- 10) Koizumi, Y.: One Case of Umbilical Adenocarcinoma Metastatic, *The Japanese Journal of Dermatology*, 95: 1027, 1985
- 11) Sasaki, K.: One Case of Umbilical Metastasis of Transverse Colon Cancer, *Acta Dermatologica*, 82: 660, 1987
- 12) Kanazawa, M., T. Nomizu, H. Kanno, et al.: One Case of a Patient with Juvenile Cancer of Transverse Colon (Sister Mary Joseph's Nodule, SMJN), *Japan Journal of Cancer Clinics*, 38: 179-186, 1992
- 13) Kajimoto, Y., T. Fukuda, T. Satomi, et al.: One Case of Colorectal Cancer Found in Umbilical Metastasis (Sister Mary Joseph's Nodule), *Proceedings of Kochi Municipal Hospital*, 17: 49-52, 1993
- 14) Mizushima, J., T. Nogita, M. Kawashima, et al.: One Case of Sister Mary Joseph's Nodule, *Rinsho Derma (Tokyo)*, 37: 1731-1733, 1995

- 15) Meguro, E. et al.: One Case of Umbilical Metastasis (Sister Mary Joseph's Nodule) that Preceded the Diagnosis of Sigmoid Colon Cancer, *J. Iwate Med. Ass.*, 50 (3): 341-346, 1998

This paper is a translation of an article in *Clinical Pharmacology and Therapy*, Vol. 14/No. 3/May 2004.